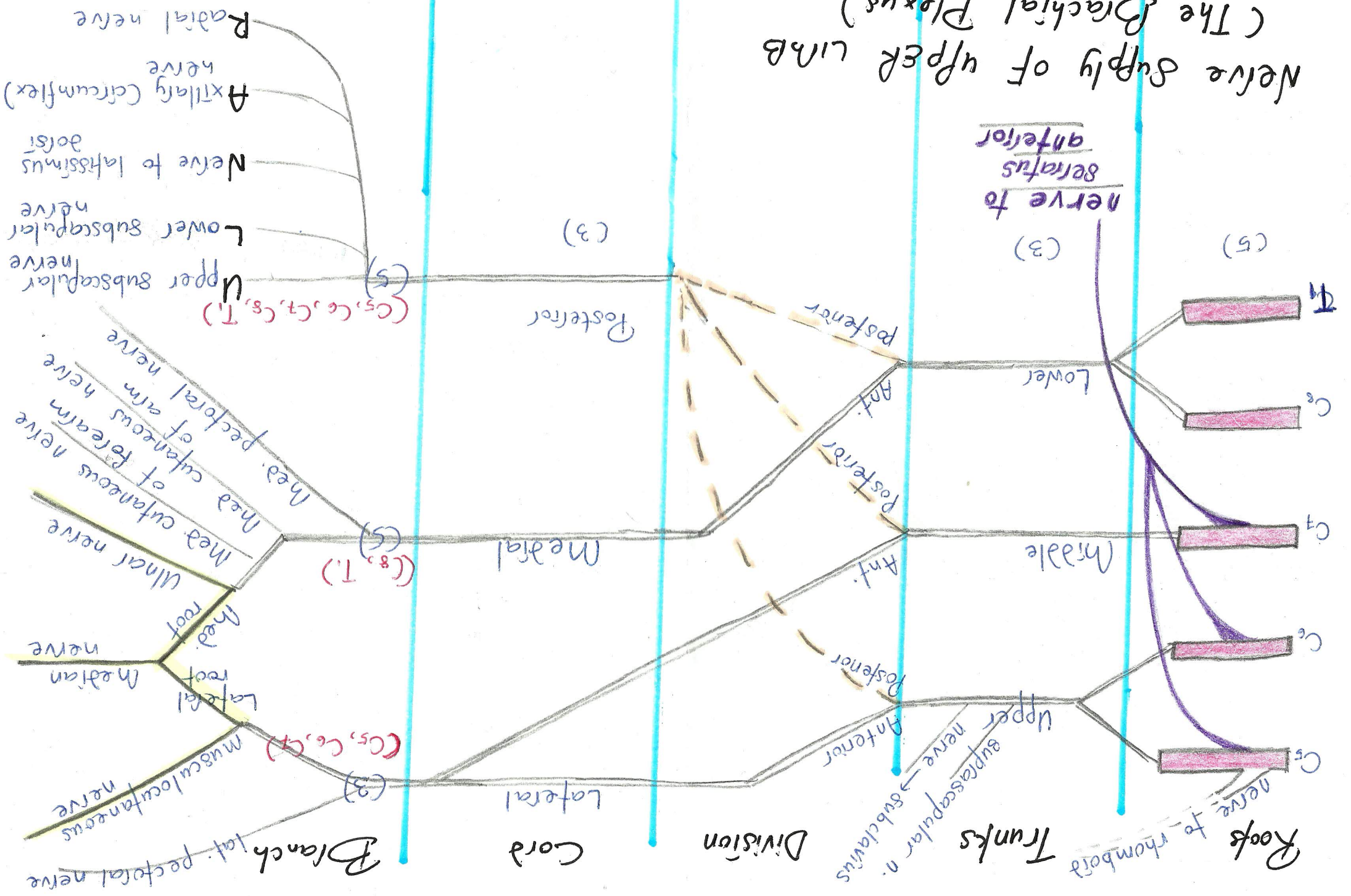



# Nerve supply of upper limb (The Brachial Plexus)





branches of Lat cord

③

Medial Root of MN

Lateral Root of MN

0105671448

EL Saged Network

Medial

⑤

ulnar N

Radial N

Medial root N

cut N of arm

from

Upper subsc

Lower

to

Lat. dors

AK

Radial

Post cord

③

